

Lipohyperplasia of the ileocecal valve as a cause of intussusception

P. Katsinelos, G. Paroutoglou, G. Jouvaras, A. Beltsis, K. Mimidis, B. Papaziogas, P. Tsoikas, I. Pilpilidis, E. Kamberis

Department of Endoscopy and Motility Unit, Central Hospital, Thessaloniki, Greece.

Abstract

We present a case of lipohyperplasia of the ileocecal valve causing episodes of intussusception, and visualized by abdominal ultrasound and CT as a “target-like” appearance. At surgery, a large yellow soft mass was in the region of the ileocecal valve, raising the suspicion of lipohyperplasia. Resection of the fatty tissue from the ileocecal valve was performed at operation, after histologic diagnosis on frozen section. Our case suggests that limited resection removing the terminal ileum is effective and preferable to more extensive resection. (*Acta gastroenterol. belg.*, 2005, 68, 233-235).

Key words : lipohyperplasia, ileocecal valve, intussusception.

Introduction

Lipohyperplasia of the ileocecal valve (ICV) is due to an excess of adipose tissue in the submucosa, producing thickening and protruding of the valve which protrudes into the cecum; microscopically, the adipose tissue is not encapsulated as in true lipomas and fades away on both sides of the valve; occasionally this is accompanied by congestion of the thickened wall with erosion of the overlying mucosa (1). Many patients who have lipohyperplasia of the ileocecal valve are asymptomatic or have only insignificant symptoms. We describe a case of lipohyperplasia of the ileocecal valve in a 31-year-old man, who presented with intussusception.

Case Report

A 31-year-old man without previous medical problems, presented with a 10-day history of diffuse abdominal colicky pain, associated with nausea. He denied any fever, chills, vomiting, or food intolerance during these days, but he was unable to perform his duties at work. He had never had abdominal surgery and his social history was negative for alcohol abuse, tobacco, or illicit drugs.

Physical examination revealed a young man with normal weight, normal temperature, and a mild tenderness in the right iliac fossa. Rectal examination was essentially unremarkable. Laboratory data were within normal limits.

Flat and up-right plain abdominal X-rays showed partial small bowel obstruction. Barium enema with air contrast showed a radiolucent round mass arising from the ileocecal valve. The patient underwent colonoscopy

interrupted at the level of the hepatic flexure because of intolerable abdominal pain. A subsequent abdominal echo (Figure 1) and CT scan (Figure 2) demonstrated a mass, possibly of the ileocecal valve, with a “target-like” appearance, produced by a high density tissue mass inside the lumen, separated from the outer wall by a low density ring.

On account of the impression of a benign tumor of the cecum, the patient underwent exploratory laparotomy three days later, following adequate bowel preparation. At surgery, a large yellow soft mass was felt in the region of the ileocecal valve, and the suspicion of lipohyperplasia of the ileocecal valve was raised (Figure 3). Conservative resection of the terminal ileum and cecum was performed. After the pathologist reported the mass to be benign, side-to-side anastomosis of the terminal ileum with the ascending colon was carried out. Histopathology of the cecal lesion showed diffuse lipomatous deposition in the ileocecal valve, fibroblastic reaction and ulceration of the overlying mucosa (Figure 4).

Discussion

Lipohyperplasia of the ileocecal valve (ICV), also known as lipomatosis, is characterized by diffuse annular infiltration of fatty tissue, mainly in the submucosa layer (2). From a histologic point of view, a difficult problem lies in the distinction between true encapsulated lipoma of the cecum and unencapsulated lipohyperplasia of the ileocecal valve. In some instances both these benign lesions are highly vascularized, showing a pathologic neovasculature of the cecum level on selective superior mesenteric artery angiography.

Lipohyperplasia of the ICV tends to be more common in females, and this is similar to the female preponderance found in lipomas of the gastrointestinal tract (3). Several reports have previously shown the rarity of ileocecal lipohyperplasia before the age of 40, as it is usually seen between the age of 50 and 70 years (2-4). Obesity and disturbance of lipid metabolism have

Corresponding author : Panagiotis Katsinelos, Head, Department of Endoscopy and Motility Unit, Central Hospital, Ethnikis Aminis 41, T.K. 54635 Thessaloniki, Greece. E-mail : pantso@the.forthnet.gr.

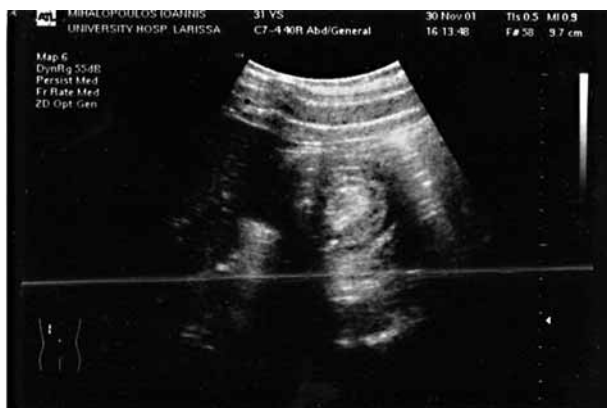

Figure 1. — Ultrasound transverse of the lower abdominal quadrant shows a target-like image with an echogenic nucleus separated from the outer echogenic elements by an anechoic ring.

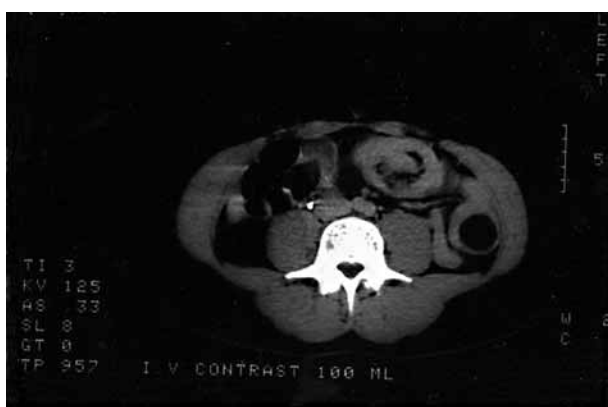

Figure 2. — Abdominal CT showing a target-like pattern in the area of the cecum.

been proposed to be associated with ICV lipohyperplasia, which correlates to some extent with right ventricular and pancreatic fatty infiltration (5). However, Tawfik and McGregor (2), in a study of 8 cases of ICV lipohyperplasia found no definite correlation with left ventricular, adrenal or lymph node fatty infiltration, or with hepatic fatty changes, body height, age of patient, or blood glucose level.

Lipohyperplasia of the ICV is rarely encountered clinically, although it is a reasonably common autopsy finding (40% moderate and 14% marked lipohyperplasia) and is the most common cause of prominent or enlarged ileocecal valve (6). However, Lasser and Rigler (7) described various combinations of abdominal pain, nausea, vomiting, distension, diarrhea, constipation and bleeding associated with lipohyperplasia of the ileocecal valve and named it “ICV syndrome”. Lipohyperplasia of the ICV has been reported to cause appendicitis (8), intestinal hemorrhage (9), intestinal obstruction (10,11) or to simulate Crohn’s disease (12).

Preoperative diagnosis of a symptomatic lipohyperplasia of ICV is difficult and it is often mistaken for car-

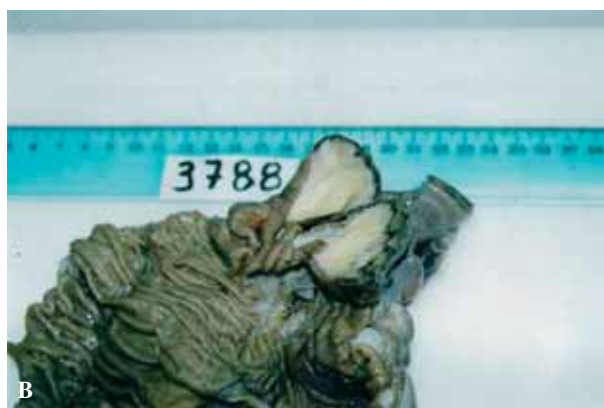
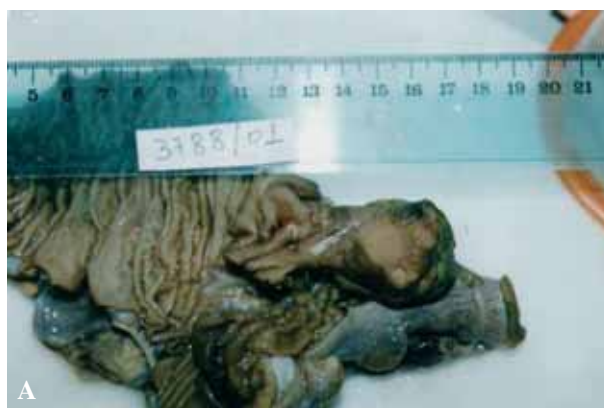
Figure 3. — (A) Gross appearance of the resected ileocecal region with a large ileocecal valve (six times the normal size) with ulceration. (B) After opening the ileocecal valve, an extensive lipohyperplasia is demonstrated.

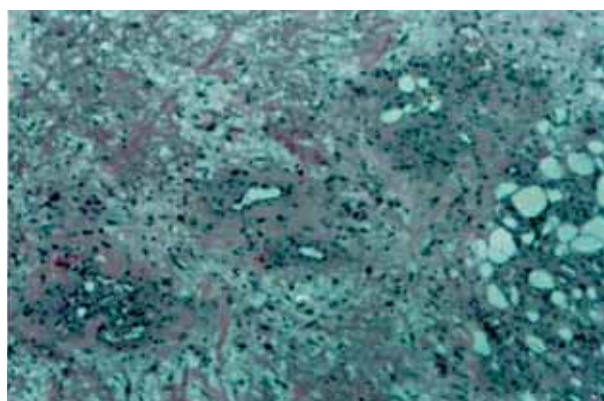


Figure 4. — Histologic examination of the ileocecal valve shows hyperplasia of the adipose tissue with inflammatory and fibroblastic reaction (Original magnification $\times 400$).

cinoma (13), Crohn’s disease (12) or angiodysplasia. Colonoscopy may be helpful since the prominent valve covered by normal or congested mucosa may be seen directly; it appears to be soft and changes its shape when touched with a biopsy forceps; biopsy specimens show normal mucosa on histologic study (14).

As a consequence, some patients with a hypertrophic valve undergo laparotomy because of the difficulty to

exclude malignancy (13). Our case is the second reported lipohyperplasia of the ICV causing intussusception in the ileocecal region. Walke and Christie (15) described a patient who had recurrent bouts of intussusception over a period of seven years, causing gastrointestinal symptoms and a palpable mass, eventually requiring surgical treatment.

It is interesting that our patient is the youngest reported with symptomatic lipohyperplasia of the ICV. Furthermore, he was male, non-obese and with normal values of glucose, cholesterol and triglycerides.

Although a preoperative diagnosis of intussusception was made in our patient according to the characteristic findings of ultrasonography and computed tomography, the etiology of the intussusception was not clear preoperatively. Our case highlights the need to be aware of lipohyperplasia of the ICV as a cause of intussusception.

References

1. Masson BC, Dawson IMP, Spriggs AI. Large intestine non-epithelial tumors. In Masson BC, Dawson IMP, Spriggs AI eds. *Gastrointestinal Pathology*. 2nd Edition. Oxford : Blackwell Scientific Publications, 1979 : 681-692.
2. Tawfik OW, McGregor DH. Lipohyperplasia of the ileocecal valve. *Am J Gastroenterol* 1992 ; 87 : 82-7.
3. Boquist L, Bergdahl L, Anderson A. Lipomatosis of the ileocecal valve. *Cancer* 1972 ; 29 : 146-40.
4. Hulten J. Lipomatosis of the ileocecal valve. *Acta Chir Scand* 1965 ; 192 : 104-11.
5. Zettergren L. Lipohyperplasia of the ileocecal valve. *Acta Soc Med Uppsala* 1953 ; 59 : 61-8.
6. Ryan J, Martin JE, Pollock DJ. Fatty tumors of the large intestine : A clinicopathological review of 13 cases. *Br J Surg* 1989 ; 76 : 793-6.
7. Lasser EC, Rigler LG. Ileocecal valve syndrome. *Gastroenterology* 1955 ; 28 : 1-16.
8. Smith SR, Fenton L. Lipohyperplasia of the ileo-cecal valve causing appendicitis. *Aust N Z J Surg* 2000 ; 70 : 76-7.
9. Pompili M, Rapaccini GL, De Vitis I, Mazzano MA, De Luca F, Gasbarrini G. Lipohyperplasia of the ileocecal valve as a cause of intestinal haemorrhage : an ultrasound Doppler study. *Ital J Gastroenterol* 1995 ; 27 : 75-7.
10. Mylonakis BJ, Karkanas GG, Katergiannakis VA, Manouras AJ, Apostolidis NS. Lipomatosis of the ileocecal valve leading to episodes of partial small bowel obstruction. *Mt Sinai J Med* 1995 ; 62 : 302-4.
11. Shah IC, Shah AM, Pardanani RH, Creedon JJ. Lipomatosis of the ileocecal valve causing recurrent small bowel obstruction. *Int Surg* 1985 ; 70 : 81-2.
12. Bhupalan AJ, Forbes A, Lloyd-Davis E, Wignall B, Murray-Lyon IM. Lipomatosis of the ileocecal valve simulating Crohn's disease. *Postgrad Med J* 1992 ; 68 : 455-6.
13. Vanlierde M, Kahn D. Hypertrophic ileocecal valve simulating a malignant tumor. *S Afr Med J* 1987 ; 72 : 50-1.
14. Messer J, Wayne JD. The diagnosis of colonic lipoma : the naked fat sign. *Gastrointest Endosc* 1982 ; 28 : 186-8.
15. Walke L, Christie AJ. Lipohyperplasia of ileocecal valve, causing recurrent intussusception. *Henry Ford Hosp Med J* 1990 ; 38 : 259-61.